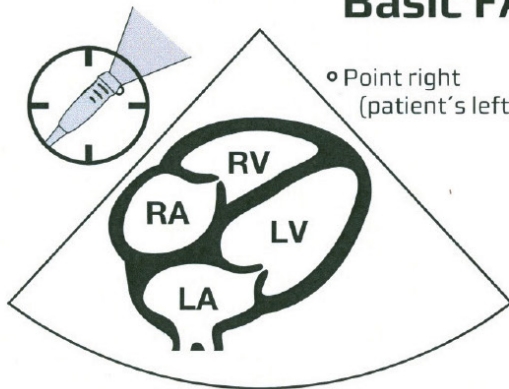


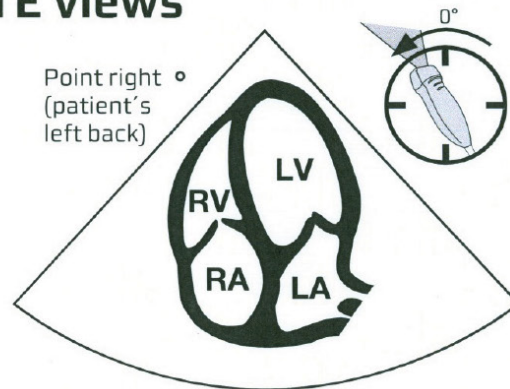
## BASIC FATE VIEWS

**Focus Assessed Transthoracic Echo (FATE)**  
Scanning through position 1-4 in the most favourable sequence

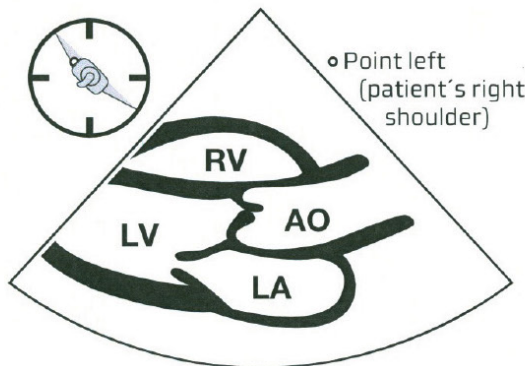
### Basic FATE views



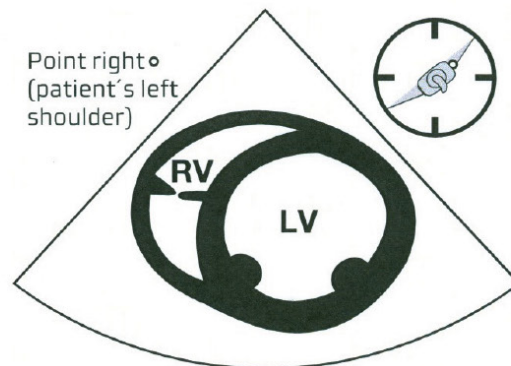
**Pos 1:** Subcostal 4-chamber



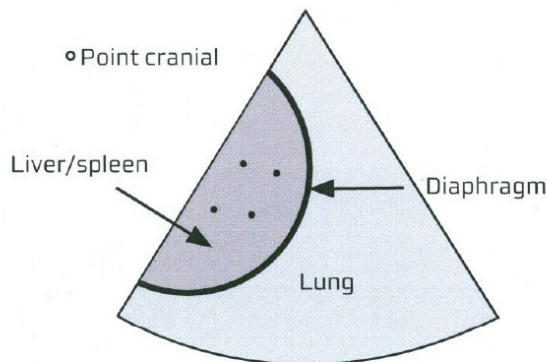
**Pos 2:** Apical 4-chamber



**Pos 3:** Parasternal long axis



**Pos 3:** Parasternal LV short axis



**Pos 4:** Pleural scanning

